

الحمد لله رب العالمين  
والصلاة والسلام على  
سيدنا محمد وآله الطيبين  
الطاهرين



**Prediction of coronary artery  
disease with tongue image analysis  
by artificial intelligence. A study  
protocol**

## ***Back ground***

- Cardiovascular diseases are the leading cause of global deaths
- Early and precise diagnosis of these disorders can significantly reduce their mortality and morbidity
- Tongue assessment in Traditional Iranian Medicine has been used to determine the patient's condition in many diseases such as heart diseases
- Tongue serves as a reflecting indicator of the body's physiological and clinicopathological status
- objective and standardized evaluation proved to be a difficult task
- Artificial intelligence has gained popularity in recent years are used in variety part of medicine like medical diagnosis
- Computer-assisted tongue diagnosis offers great promise for providing more consistent and objective health evaluations, particularly in fields such as heart disease assessment

**Alireza Hekmat Ardakani**

Department of Traditional Medicine, School of Persian Medicine, Tehran University of Medical Sciences, Tehran, Iran.

**Mehrdad Karimi - Corresponding**

Department of Traditional Medicine, School of Persian Medicine, Tehran University of Medical Sciences, Tehran, Iran.

**Hamidreza Hekmat**

Department of Cardiology, School of Medicine Baharlou Hospital, Ziaeian Hospital, Tehran University of Medical Sciences, Tehran, Iran.

**Armin Behnamnia**

Artificial Intelligence, Computer Engineering Department, Sharif University of Technology, Tehran, Iran.

**Kasra Arabi**

Department of Mathematical Science, Sharif University of Technology, Tehran, Iran

**Amir Homan Kazemi**

Department of Traditional Medicine, School of Persian Medicine, Tehran University of Medical Sciences, Tehran, Iran.

**Amir Sobh Rakhshankhah**

Department of Cardiology, School of Medicine, Sepehr heart center, Baharloo hospital, Tehran University of Medical Sciences, Tehran, Iran.

**Alireza Yargholi**

AICT Research Institute, Sharif University of Technology, Tehran, Iran.

**Hamidreza Rabiee**

Distinguished professor of Computer Engineering Department, Sharif University of Technology, Tehran, Iran.

## Objectives

- ▶ The primary purpose of this study is to determine the high-precision relationship between tongue sign and coronary artery disease by using AI through tongue image analysis
- ▶ It is possible to create software that can analyze the status of coronary arteries using tongue image analysis

## Methods

- This protocol adheres to the SPIRIT-AI Extension guideline

## Definitions and variables

### *Tongue examination*

- ▶ Contains nine variables: the *size* of the tongue, the *color* of the tongue, *teeth mark*, tongue *fissure*, the distribution of *tongue coating*, the *color of tongue coating*, the *thickness of tongue coating*, *moisture* of tongue, and *red spot*.

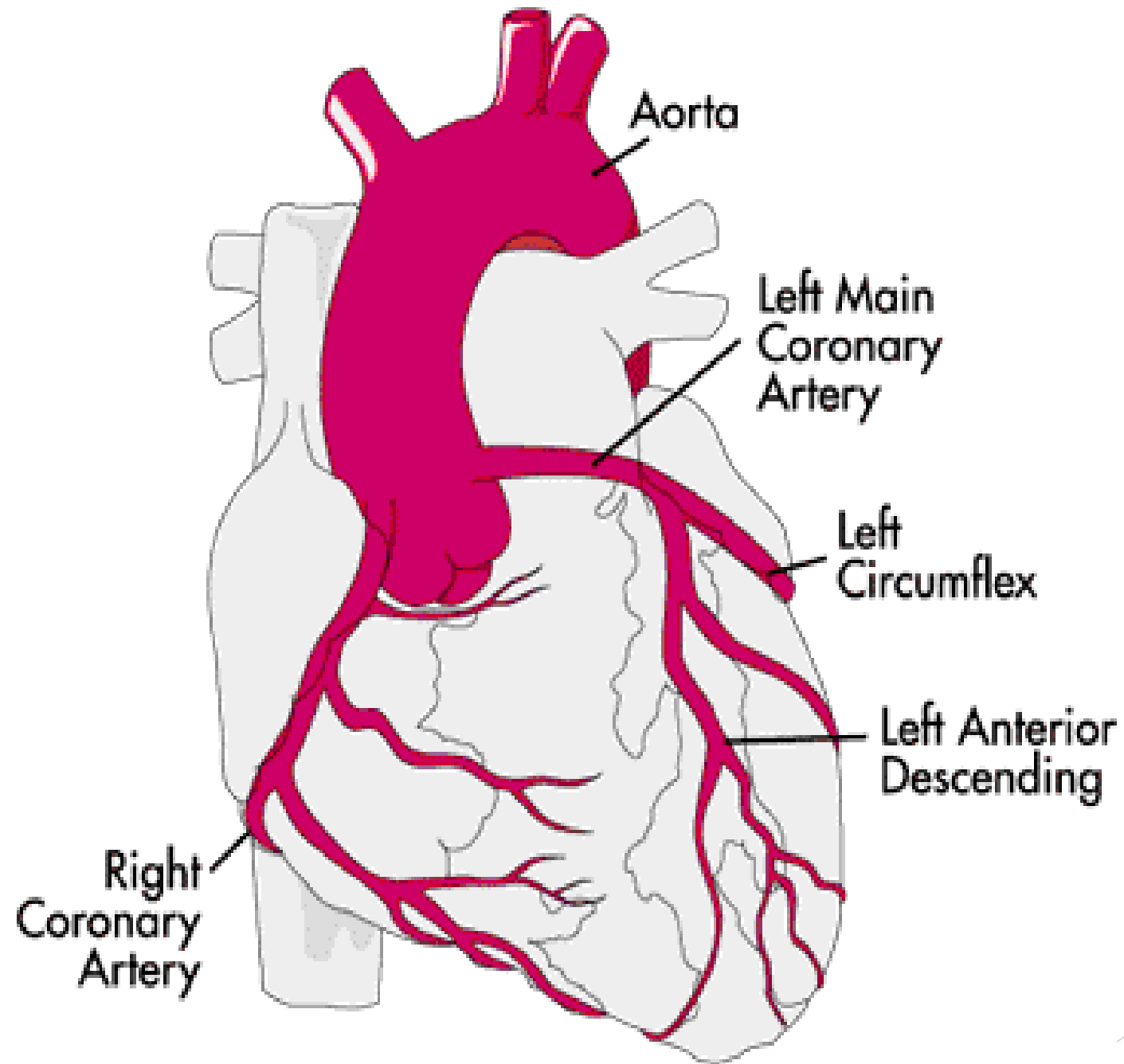
Variable	Scale				
Shape	small	Normal	Large		
Color	Pale	Red pale	Red	Dark red	Blue
Teeth mark	none	Present			
Fissure	None	Present	If present in which part of tongue		
Coating	none	Present	If present in which part of tongue		
Color of coating	Without coat	White	Yellow	gray	black
thickness of coating	Without coat	Thin	Normal	Thick	
Wetness	dry	Normal	Wet		
Red spot	None	Present	If present in which part of tongue		

## *Angiographic results*

In this study, the results of coronary angiography will be evaluated in four parts

- ▶ Left main coronary artery (LMCA)
- ▶ Left anterior descending artery (LAD) with proximal, middle, and distal segments.
- ▶ Left circumflex artery (LCX) with proximal, middle, and distal segments.
- ▶ Right coronary artery (RCA) with proximal, middle, and distal segments.





- ▶ The angiographic results of diagonal artery 1, 2, and septal branch, from LAD are not considered.
- ▶ The angiographic results of obtuse marginal (OM) 1 in the proximal part of LCX, and OM2 and ramus arteries in the middle part of LCX will be considered.
- ▶ The angiographic results of posterior descending arteries (PDA), posterior left ventricle (PLV), and RV branch in the distal part of RCA.

### **The modified Agatston score**

No luminal stenosis will be normal, 1- 49% stenosis will be mild, 50-69% stenosis will be moderate, 70-99% stenosis will be severe, and 100 % will be occlude

### **Outcome**

drug treatment, percutaneous coronary intervention (PCI), coronary artery bypass graft (CABG) and others (e.g. Premature Ventricular Contractions ablation, valve replacement, or cancellation of angiography)

Quantitative results of coronary angiography			Qualitative results of coronary angiography used in the research		
Vascular category	vessels	Quantitative value of obstruction	Vascular category	Segment of artery	Qualitative degree of obstruction (modified Agatston score)
LMCA	LMCA		LMCA	LMCA	
LAD	Prox. LAD		LAD	Prox. LAD	
	Mid. LAD			Mid. LAD	
	Distal. LAD			Distal. LAD	
	Diagonal 1				
	Diagonal 2				
	Septal B				
LCX	Prox. LCX		LCX	Prox. LCX	
	Mid. LCX			Mid. LCX	
	Distal. LCX			Distal. LCX	
	OM 1				
	OM 2				
	Ramus				
RCA	Prox. RCA		RCA	Prox. RCA	
	Mid. RCA			Mid. RCA	
	Distal. RCA			Distal. RCA	
	RV Branch				
PDA	PDA				
PLB	PLB				

## *Artificial intelligence*

### **Procedure of tongue images analyzing**

#### *-Extraction of tongue region from facial images*

Use the Segment Anything Model (SAM)

#### *-Tongue visual characteristics*

Apply a combination of classical image processing methods and deep neural networks

Utilize a Convolutional Neural Network (CNN) to extract high-level features

#### *-Semi-supervised extraction of visual features*

-Use a UNet autoencoder architecture to extract features

## Study setting

- 1- Data sheets containing demographic and past medical information, lab data, and for each participant will be prepared
- 2- A form for entering the results of the tongue examination by the researcher during imaging is prepared.

Name and Surname:

Phone:

Address:

Sex:

Age:

Weight:

Height:

BMI:

Number of breaths per minute:

Number of pulses per minute:

Blood pressure while attending the ward:

Initial diagnosis:

Do you have chest pain during the week?

Number of attacks per week/day:

Duration of attacks:

type of pain (stabbing, pressing, shooting, others: to be explained)

shortness of breath (while moving, while resting, during chest pain)

Medicines used and its duration:

Smoking and its type:

duration and quantity:

Alcohol consumption:

duration and amount:

: Results of clinical tongue examination						
1	Size (shape) of tongue	Large	Medium	Small		
2	The color of the tongue	Pale red	Red	Deep red	Purple	Blue
3	Teeth mark	Has	Has not	Which side of tongue		
4	Tongue fissure	Has	Has not			
5	Which area of tongue, if has fissure	Front of tongue	Left side	Middle of tongue	Right side	Root of tongue
6	Wetness of tongue	Excess	Normal	Less than normal		
7	Red spot on tongue	Has	Has not			
8	Scattering of red dots	front of tongue	left side	middle of tongue	right side	root of tongue
9	Tongue coating	Has	Has not			
10	Color of the coating on the tongue	No coating	White	Yellow	Gray	Black

11	Place of tongue coating	Front of tongue	Left side	Middle of tongue	Right side	Root of tongue
12	Thickness of the tongue coating	No coating	Thin	Normal	Thick	
13	Speed of speech	Fast	Normal	Slower than normal		
14	Feeling heavy in tongue	Yes	No			
15	Taste changes	Yes	No			
16	Special taste sensation	Yes	What a taste	NO		
17	Deviation of tongue	Yes	What side	NO		
18	Trembling in tongue	Yes	Up and down	Left and right	No	
19	Presence of lesion on tongue	Yes	Which area	No		
20	Appearance of tongue	Ellipse	Round	Rectangle	Square	Hammer
		Triangular	Open Triangular			



## Eligibility criteria

**Inclusion criteria:** Patients hospitalized in the angiography department who are hemodynamically stable will be included in the study

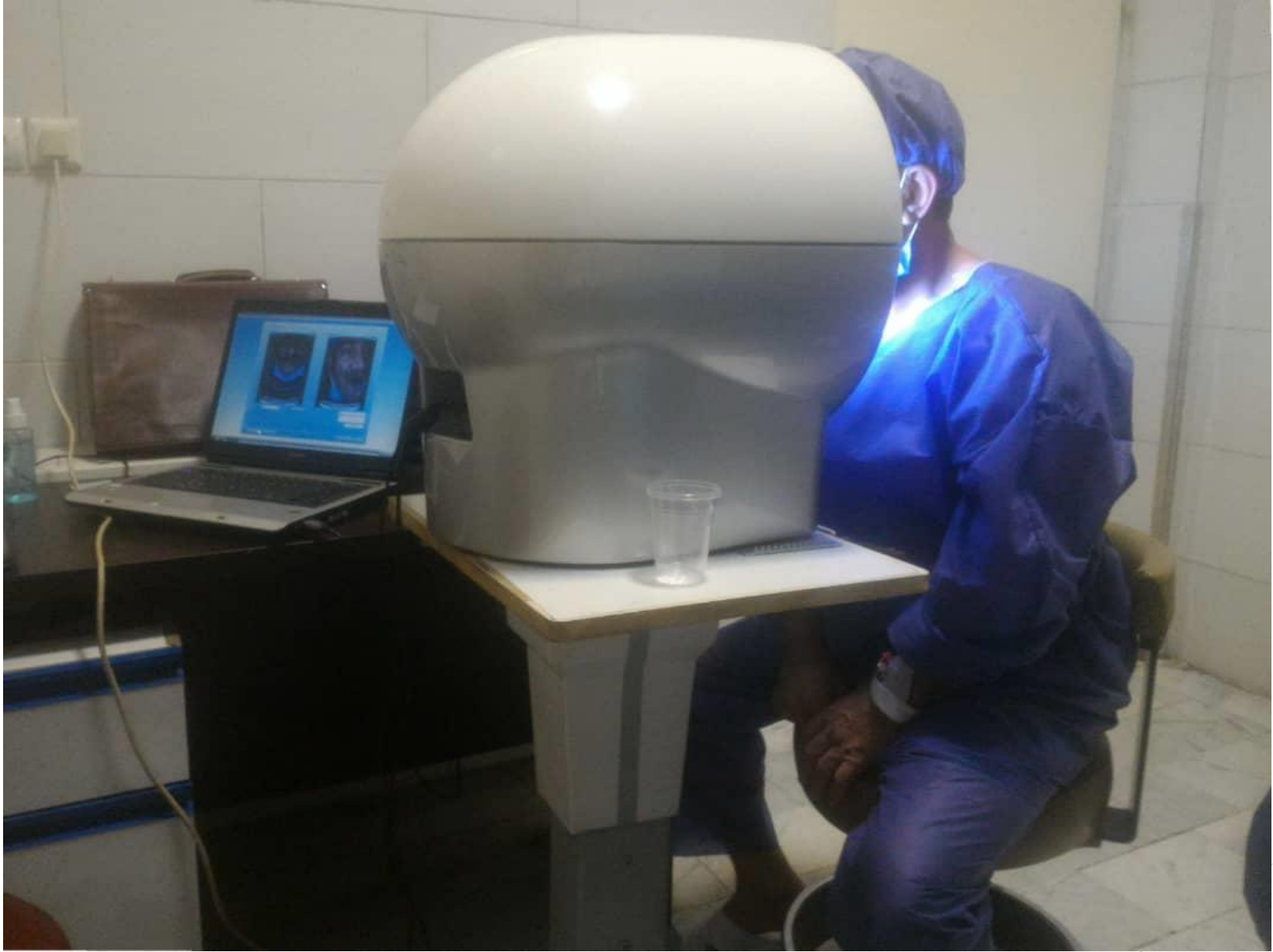
**Exclusion criteria:** Patient non-cooperation, Unconscious or hemodynamically unstable patient, Cognition or behaviorally impairment, active cancer or active oral infection, oral cancer related symptoms in past 2 year, pregnancy or lactation, congenital heart disease, geographic tongue

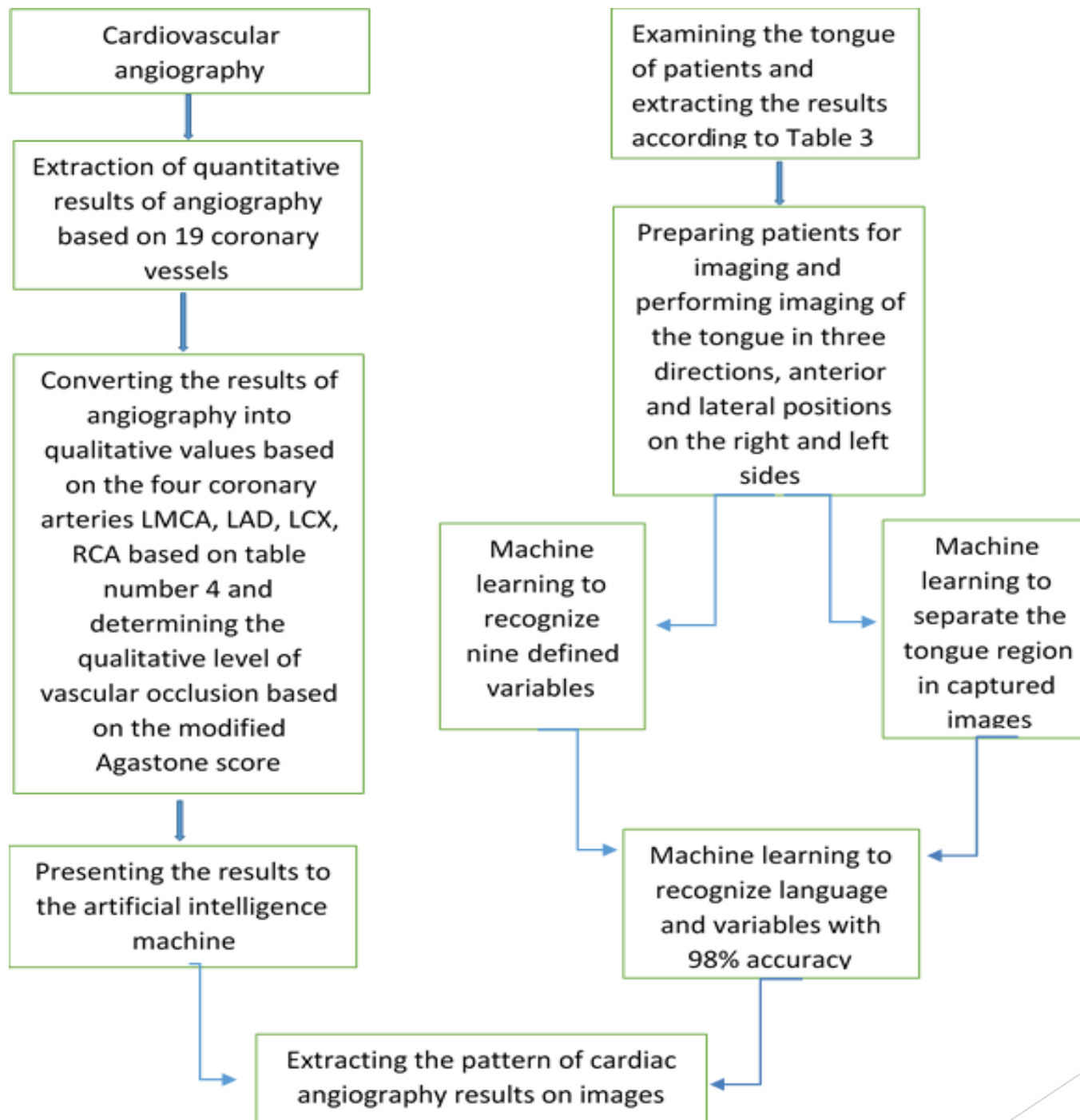
## Sample size

Sampling will continue until the AI software recognizes the tongue images and their characteristics. However, our preliminary estimate is between “900 to 1200”.

## Data collection

- ▶ Patients who meet the entry criteria will complete the consent form
- ▶ medical history and demographic information will be recorded in the relevant forms
- ▶ imaging procedure will take place in a room without windows or access to natural light
- ▶ will use the special device, which has 210 LEDs to illuminate the tongue evenly, and comes with a head and chin support for photography
- ▶ The photos of the tongue from the front, right, and left sides in the same direction will be taken
- ▶ To train the AI machine, in easily identifiable variables such as color, shape, and coating. We plan to use around 300 to 500 images for this purpose. Other variables like fissures, red spots, teeth marks, and moisture on the tongue, we will draw upon a database of over 5000 tongue images.





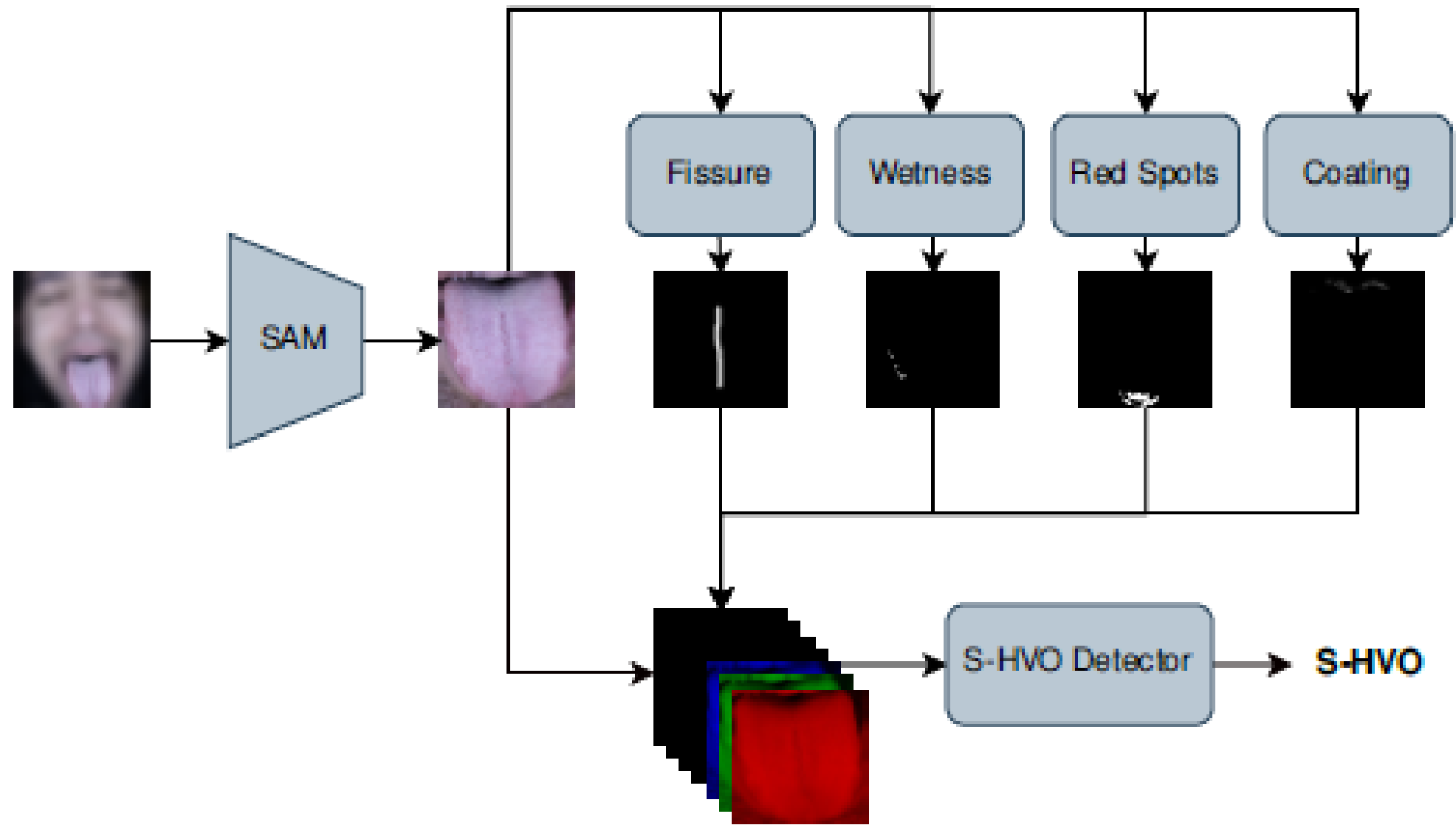


Figure 1. Overall pipeline of the proposed method. After extracting tongue region by SAM, different features are extracted by their corresponding models, then added to the tongue image and all together given to the S-HVO classifier to detect severe occlusion in coronary arteries.

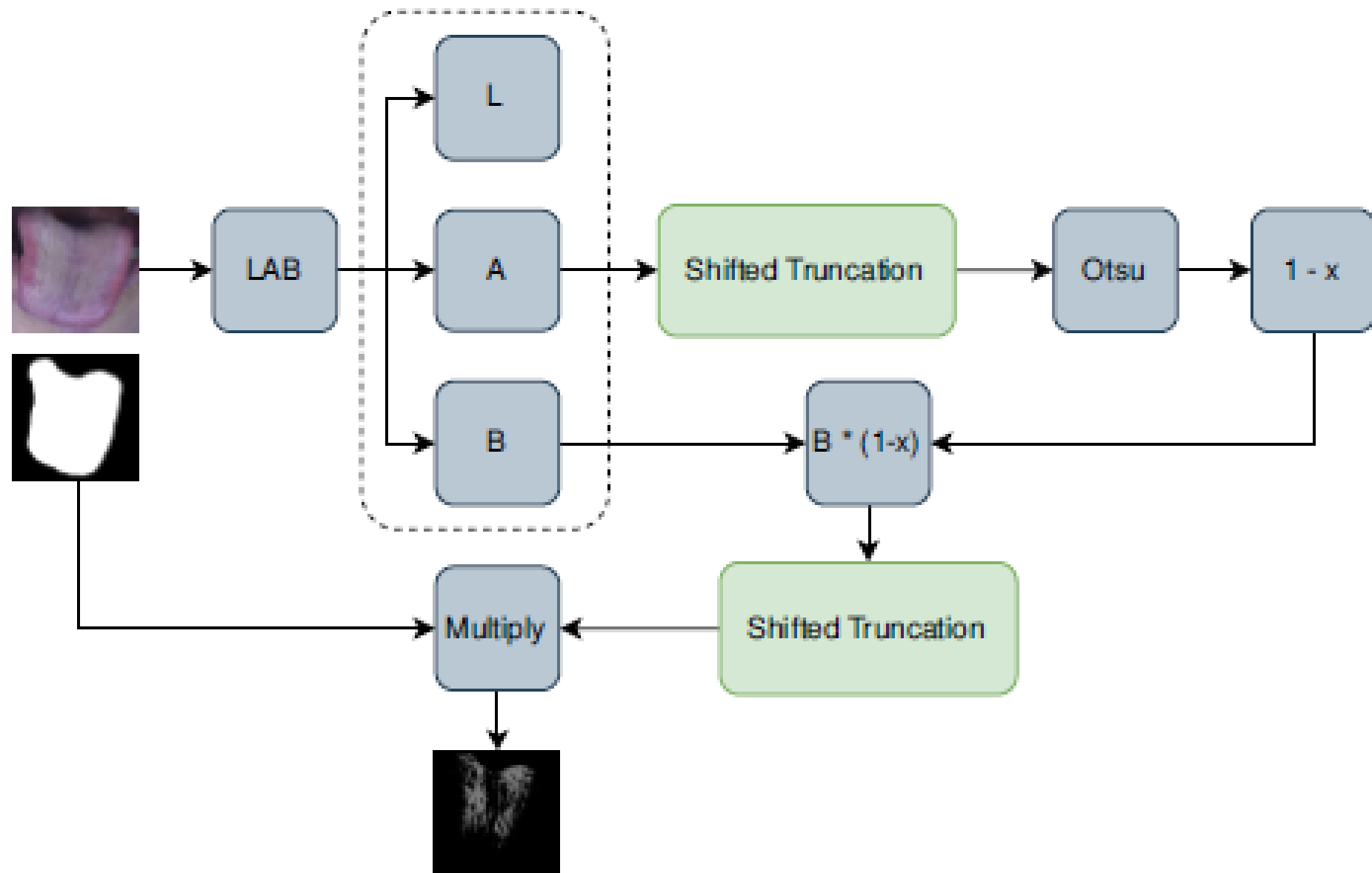


Figure 3. Procedure to extract coating from tongue image. Regions with low red color and high yellow color are considered as coating. The contrast from a normal tongue color indicates the intensity and thickness of the coating.

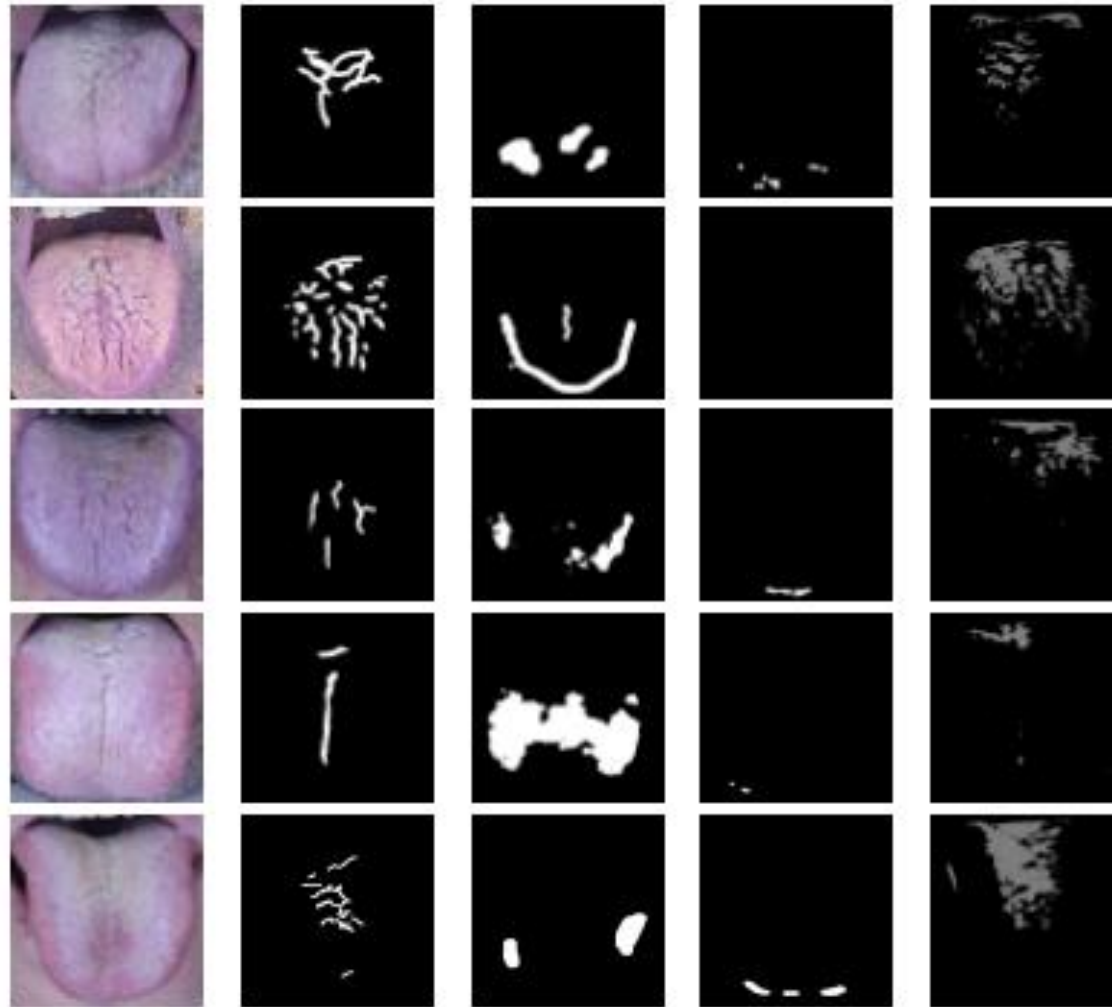


Figure 4. Visualization of tongue characteristics on four example images. In Each row, from left to right, 1. tongue image, 2. fissures, 3. wetness, 4. red spots, 5. coating are shown.

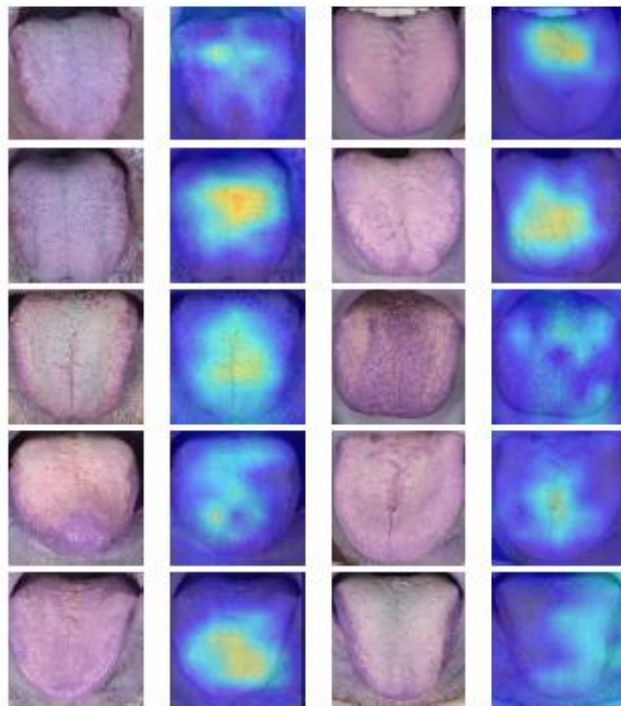


Figure 5. Grad-CAM results on our model for 10 samples of tongue image.




Figure 6. Tongue image regions illustrated on the coating mask. In order to extract numerical features for SVM, we average the binarized coating values over each region as a measure of its intensity. The same method is used for other features.



Table 1. S-HVO Classification Results

	Accuracy	Precision	Recall	F1 score
Raw image	45%	66%	45%	53%
SVM	62%	60%	88%	71%
Ours (image+features)	<b>71%</b>	<b>72%</b>	<b>97%</b>	<b>83%</b>

Table 2. Effect of the removal of each feature on the performance of our proposed model

	Accuracy	Precision	Recall	F1 score
Wetness removed	65%	70%	86%	77%
Fissure removed	62%	71%	77%	74%
Red Spots removed	68%	74%	83%	78%
Coating removed	56%	69%	69%	69%
Ours (image+features)	<b>71%</b>	<b>72%</b>	<b>97%</b>	<b>83%</b>

Table 3. Effect of the removal of each feature on the performance of SVM model

	Accuracy	Precision	Recall	F1 score
Wetness removed	59%	58%	89%	70%
Fissure removed	58%	58%	88%	70%
Red Spots removed	60%	59%	<b>89%</b>	<b>71%</b>
Coating removed	53%	54%	88%	67%
SVM	<b>62%</b>	<b>60%</b>	88%	<b>71%</b>

Table 4. Effect of the removal of each region on the performance of SVM model

	Accuracy	Precision	Recall	F1 score
Bottom left removed	60%	59%	88%	70%
Bottom center removed	60%	59%	86%	70%
Bottom right removed	60%	58%	<b>89%</b>	71%
Top left features removed	53%	54%	88%	67%
Top center features removed	54%	55%	86%	67%
Top right features removed	57%	57%	88%	69%
SVM	<b>62%</b>	<b>60%</b>	88%	<b>71%</b>

## Discussion

- ▶ To aid in the quick diagnosis and treatment of CVD.
- ▶ could lead to the development of software that can be installed on cellphones and, by taking a picture of a patient's tongue, analyze the risk of CVD.
- ▶ This is a diagnostic assistance tool that, in conjunction with other diagnostic aids such as an electrocardiogram.
- ▶ This program is quite valuable, particularly in individuals who have non-specific cardiac symptoms yet are at risk of CAD. The findings of this study will enhance the physical and mental well-being of society and decrease treatment and rehabilitation expenses


**Input** *The images of patients tongue  
Cardiac  
angiographic  
results*

**Process** *Finding the  
possibility of  
blockage in  
coronary arteries  
by AI*

**Out put** *Improved  
detection of  
potential blockage  
in the coronary  
artery*

**Out come** *Reducing  
the incidence of  
mortality and physical  
and mental  
disabilities resulting  
from coronary artery  
blockage*

**Impact** *Enhancing  
community health  
and lowering  
treatment and  
rehabilitation  
expenses*



از توجه شما متشکرم